



# “Extant of the living dead”: a case report on Cotard’s syndrome and its treatment aspects from a tertiary care hospital in India

## Abstract

Cotard’s syndrome has always borne a historical construct, being linked to pure psychosis, affective disorders as well as organic disorders like Parkinson’s, temporal lobe epilepsy, migraine, and cerebral infarction. Emphasis has remained on the psychopathology, involving beliefs of negation, damnation, guilt, and denouncing of body organs. Treatment aspects has been focused on less frequently; moreover, sparsely from India. We present a case of bipolar affective disorder, current episode severe depression with psychotic symptoms (Cotard’s syndrome) with special focus on treatment.

**Keywords:** Suicide. ECT. Antipsychotics.

**Keya Das, P Liji, VSSR Ryali**

*Department of Psychiatry, PESIMSR, Kuppam, Andhra Pradesh, India*

**Correspondence:** Dr. Keya Das, G 02, Tuscan East Apartments, Lazar Road, Cox Town, Bangalore-560042, Karnataka, India. drkeyadas@gmail.com

**Received:** 22 May 2019

**Revised:** 9 January 2020

**Accepted:** 6 February 2020

**Epub:** 17 February 2020

## INTRODUCTION

History documents that the entity Cotard’s syndrome is bequeathed by the Gallo Neuro-psychiatrist Julius Cotard (1840-1889) who in his 1880 lecture at a Société Médico-Psychologique meeting presented the case of a lady aged 43 years who denied existence of her organs, claiming she was only skin and bones, and also, denied the existence of her own soul, the god or the devil. She further held the belief that her body could not die a natural death and the only way to free herself from mortal existence was to immolate herself.[1] At the outset, Cotard ascribed the case as “délire hypochondriac” (hypochondriac delirium), believing it as “lypemanie”, a type of psychotic depression.[2] Two years hence, Esquirol termed the same as “délire des négations” (delirium arniseon).[3] In 1893, Emil Régis coined the term “délire de Cotard” (delirium of Cotard)[4] following the demise of Cotard, to describe presentations with anxious melancholia, delusions of absence of organs, negation, damnation, and immortality although the eponym Cotard’s syndrome was originally coined by Seglas in 1887.[1] We present a case of Cotard’s syndrome with bipolar affective disorder, and highlight the treatment aspects as per historical evolution along with specific treatment aspects in our case.

## CASE HISTORY

A 40-year-old widow, a coolie worker currently unemployed since past year with poor social support, hailing from low socioeconomic status with moderately well-adjusted personality with no significant psychiatric family history presented to the psychiatry outpatient department (OPD) with history of feeling persistently sad, associated crying spells, death wish, poor sleep and appetite, and inability to work over

the last one year. Worsening of symptoms for six months with complaints that her uterus was rotten and leaking was reported. According to her, bones were malformed, she did not have a backbone, associated severe back pain and hence, she could not sit or walk. She reported of having shrunken and shrivelled body as that of the very old and expressed guilt over sexual activities, stating that her lower body was now destroyed as a result of such acts. Suicidal ideas and one suicide attempt by self-immolation was discovered three months back, which had resulted in minor burns. Past history revealed similar episode of crying spells, death wish, sense of worthlessness, hopelessness, and auditory hallucinations, three years back for which patient had been admitted in psychiatric care and received three electroconvulsive therapies (ECTs) and pharmacotherapy, with remission of symptoms. Further, three episodes of excessive cheerfulness, overfamiliarity, hypersexuality in the form of soliciting multiple partners. Frequent altercations with family over this was reported by the informants, having occurred 13 years, eight years, and two years back, respectively.

For her present symptoms, several religious therapies were sought and patient visited multiple gynaecologists for her uterine ailments, documents stating reassurance and no organicity, and referral to psychiatry on two occasions. On examination, patient was dishevelled, had poor hygiene, made eye contact fleetingly, was elaborative only with female psychiatrists, wailing throughout the interview, expressing repeatedly that her lower body was rotten and purulent, particularly her uterus, and these ailments had befallen her as a direct consequence of her sexual behaviour with strange men, that it was hopeless and she was better off dead than bringing further disgrace to her family. Her speech, though relevant and coherent, was reduced in quantity and tone.

Mood was depressed with delusion of guilt and damnation, nihilistic delusions, anhedonia, worthlessness, hopelessness, helplessness, and active suicidal ideations were recorded. Insight and judgement were impaired. She was admitted and underwent blood investigations that included complete blood count, blood glucose level, liver function test, renal function test, human immunodeficiency virus (HIV), HBsAg, and thyroid function test which were within normal limits. Her computed tomography (CT) scan of brain, chest X-ray, and ultrasound abdomen were unremarkable. The X-ray

of lumbar spine was done to evaluate her back pain which suggested lumbar spondylosis. A final diagnosis of bipolar affective disorder, current episode severe depression with psychotic symptoms (Cotard's syndrome) was made as per the tenth revision of the International Statistical Classification of Diseases and Related Health Problems (ICD-10).[5] Treatment was initiated and improvements were noted with use of Beck's Depression Inventory (BDI),[6] the Scale for Suicide Ideation (SSI),[7] and Brown's Assessment of Beliefs Scale (BABS)[8] (Table 1).

**Table 1:** Timeline of treatment and improvement

Timeline	Treatment	Improvement	Scales' score
Day 1 - day 2	Tab risperidone 4 mg, tab clordiazepoxide 20 mg in divided doses	Nil	BDI: 54 SSI: 35 BABS: 22
Day 3 - day 7	Tab amitriptyline 100 mg, tab risperidone 4 mg, tab clordiazepoxide 10 mg HS	Ill-kempt, wailing during interview reduced, mood depressed, socially withdrawn, suicidal idea +++++, delusion of guilt +++++, nihilistic delusion +++++	BDI: 54 SSI: 35 BABS: 22
Day 8	1st ECT	Suicidal idea +++, delusion of guilt +++++, nihilistic delusion +++++	BDI: 48 SSI: 22 BABS: 22
Day 9 - day 11	Tab amitriptyline 150 mg, tab risperidone 4 mg	Mood depressed but reactive and no wailing, personal care and hygiene maintained	
Day 12	2nd ECT	Suicidal idea ++, delusion of guilt ++, nihilistic delusion +++++	BDI: 38 SSI: 18 BABS: 22
Day 13 - day 14	Tab amitriptyline 150 mg, tab risperidone 4 mg	Mood depressed but reactive, social interaction improved	
Day 15	3rd ECT	Death wish +, delusion of guilt +/-, nihilistic delusion ++	BDI: 32 SSI: 8 BABS: 13
Day 16 - day 17	Tab amitriptyline 150 mg, tab risperidone 4 mg	Mood depressed but reactive, social interaction improved	
Day 18	4th ECT	No suicidal ideation, death wish +/-, no delusion of guilt, nihilistic delusions +	BDI: 28 SSI: 0 BABS: 6
Day 19 - day 20	Tab amitriptyline 150 mg, tab risperidone 2 mg	Mood anxious and reactive, social interaction improved	
Day 21	5th ECT	No suicidal ideation, no delusion of guilt, no nihilistic delusion	BDI: 22 SSI: 0 BABS: 0
Day 22 - day 24	Tab amitriptyline 150 mg, tab risperidone 2 mg	Mood euthymic with social interaction	
Day 25	6th ECT	No suicidal ideation, no delusion of guilt, no nihilistic delusion, mood euthymic with social interaction	BDI: 11 SSI: 0 BABS: 0
Day 26 - day 34	Tab sodium valproate 1000 mg, tab amitriptyline 150 mg	No suicidal ideation, no delusion of guilt, no nihilistic delusion, mood euthymic with social interaction	BDI: 5 SSI: 0 BABS: 0

BDI=Beck's Depression Inventory, SSI=the Scale for Suicide Ideation, BABS=Brown's Assessment of Beliefs Scale, ECT=Electroconvulsive therapy

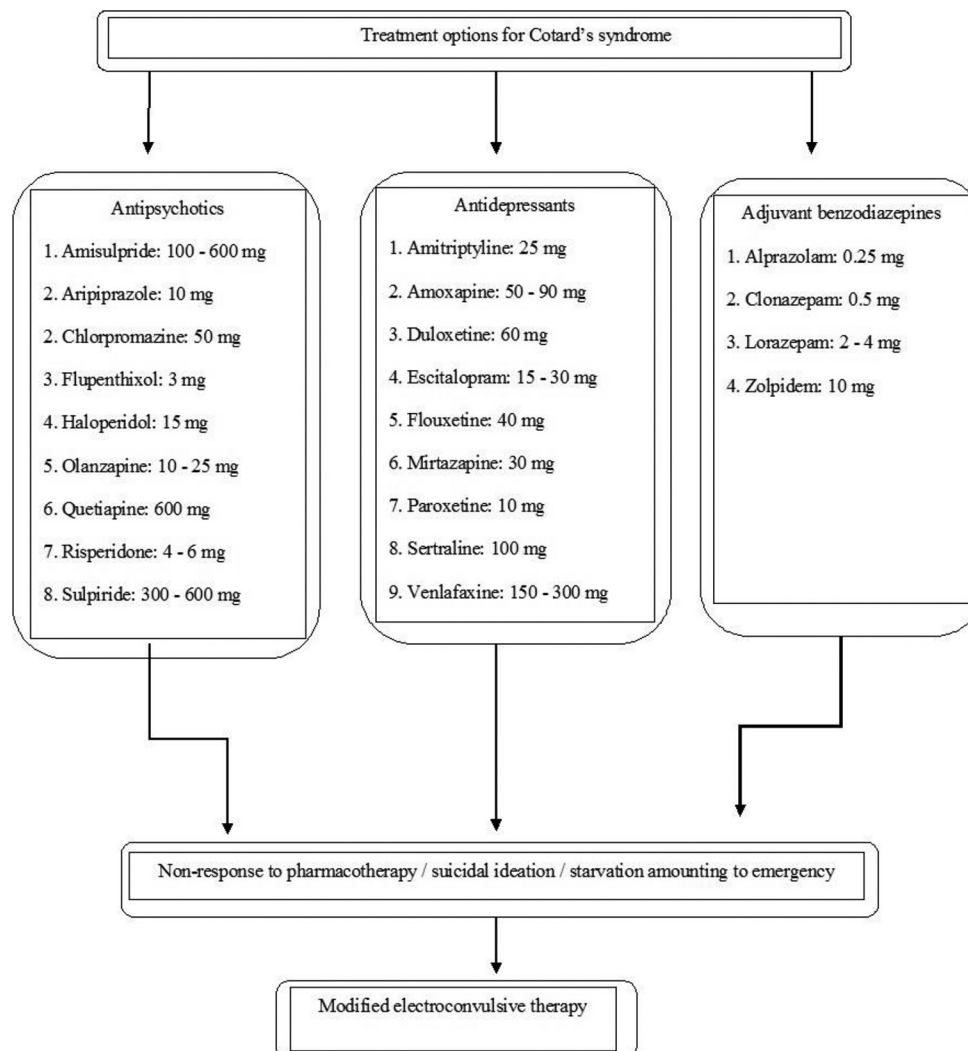
## DISCUSSION

Time and evolution have garnered fierce debate as to whether Cotard's syndrome be considered as a separate nosological entity or as a subsyndrome of the depressive, schizophrenic, or psycho-organic disorder. Lacking consensus, Cotard syndrome has been denied a diagnostic autonomy within the fourth or fifth edition of the Diagnostic and Statistical Manual of Mental Disorders (DSM-IV or DSM-5)[9,10] and ICD-10,[5] and continues being described as subsyndrome in schizophrenia[11] and organic disorders,[12] but especially in patients suffering from severe mood disorder.[13] In DSM-IV-TR,[14] nihilistic delusions are categorised as mood congruent delusions within a depressive episode with psychotic features.

In 1995, based on a retrospective factor analysis of 100 cases in literature, Berrios and Luque[3] subdivided Cotard's syndrome into three types. First, classical Cotard's syndrome included a form of psychotic depression, characterised by anxiety, melancholic delusions of guilt, and auditory hallucinations. Our case appeared to fall under this type. Secondly, Cotard's syndrome type I that was associated

with hypochondriac and nihilistic delusions, and absence of depressive episodes. Thirdly, Cotard's syndrome type II, with anxiety, depression, auditory hallucinations, delusion of immortality, nihilistic delusions, and suicidal behaviour as characteristic features.[15]

Sound epidemiological data regarding Cotard's syndrome is lacking, with no reports from India. A Hong Kong-based prevalence study in a selected psychogeriatric population reported Cotard's syndrome in two out of 349 patients.[16] Inclusion of only severely depressed elderly recorded a prevalence of 3.2%.[16] In a Mexican study of psychiatric patients, 0.62% (n=three) revealed Cotard's syndrome.[17] The chances of Cotard's delusion emerging appear to increase with age.[18] An analysis of 100 cases reported mean age of 56 years,[3] and more recently, a mean age of 47.7 years was found in an analysis of 138 case reports.[19] Females appear to be more at risk than males. The syndrome is found across different ethnic groups.[18] Individuals below 25 years exhibiting Cotard's was construed to be associated with bipolar disorder.[19] Our case had similar findings with regard to gender being female, but was against the previous findings in terms of younger age association in bipolar affective disorder with Cotard's.



**Figure 1:** Treatment options for Cotard's syndrome.[21]

## Treatment aspects

Several reports have been published, but no randomised studies have been performed for Cotard's syndrome. The most commonly reported strategy is ECT. On the classification of Berrios and Luque,[3] a suggestion was made that ECT is indicated in patients with Cotard's syndrome and psychotic depression, while antipsychotics exert better effects in classical Cotard's.[13] Successful pharmacotherapeutic approaches have also been published, mostly with antidepressants, antipsychotics, or a combination of both.[15] Bipolar disorder should be considered in patients under the age of 25 years.[19] Adding bromocriptine to clomipramine and lithium had a beneficial effect in a patient with bipolar disorder type I.[19] Special measures may be needed due to an important risk of suicide.[20] Our case report highlights the success of a combination therapy with ECT in conjunction with antipsychotics and antidepressants in the acute phase, and sodium valproate in the maintenance phase of bipolar type I with Cotard's syndrome (Figure 1).[21]

## REFERENCES

1. Moschopoulos NP, Kaprinis S, Nimatoudis J. [Cotard's syndrome: case report and a brief review of literature]. [Article in Greek, Modern] *Psychiatriki*. 2016;27:296-302.
2. Grover S, Aneja J, Mahajan S, Varma S. Cotard's syndrome: two case reports and a brief review of literature. *J Neurosci Rural Pract*. 2014;5(Suppl 1):S59-62.
3. Berrios GE, Luque R. Cotard's syndrome: analysis of 100 cases. *Acta Psychiatr Scand*. 1995;91:185-8.
4. Berrios GE, Luque R. Cotard's delusion or syndrome?: a conceptual history. *Compr Psychiatry*. 1995;36:218-23.
5. World Health Organization. The ICD-10 classification of mental and behavioural disorders: clinical descriptions and diagnostic guidelines. 2nd ed. Geneva: World Health Organization; 2004.
6. Beck AT, Steer RA, Brown GK. Manual for the Beck Depression Inventory-II. San Antonio, Texas: Psychological Corporation; 1996.
7. Beck AT, Kovacs M, Weissman A. Assessment of suicidal intention: the Scale for Suicide Ideation. *J Consult Clin Psychol*. 1979;47:343-52.
8. Eisen JL, Phillips KA, Baer L, Beer DA, Atala KD, Rasmussen SA. The Brown Assessment of Beliefs Scale: reliability and validity. *Am J Psychiatry*. 1998;155:102-8.
9. American Psychiatric Association. Diagnostic and statistical manual of mental disorders. 4th ed. Washington, DC: American Psychiatric Association; 1994.
10. American Psychiatric Association. Diagnostic and statistical manual of mental disorders. 5th ed. Arlington, VA: American Psychiatric Association; 2013.
11. Shiraishi H, Ito M, Hayashi H, Otani K. Sulpiride treatment of Cotard's syndrome in schizophrenia. *Prog Neuropsychopharmacol Biol Psychiatry*. 2004;28:607-9.
12. Gardner-Thorpe C, Pearn J. The Cotard syndrome. Report of two patients: with a review of the extended spectrum of 'délire des négations'. *Eur J Neurol*. 2004;11:563-6.
13. Madani Y, Sabbe BG. [Cotard's syndrome. Different treatment strategies according to subclassification]. [Article in Dutch] *Tijdschr Psychiatr*. 2007;49:49-53.
14. American Psychiatric Association. Diagnostic and statistical manual of mental disorders. 4th ed. Text rev. Washington, DC: American Psychiatric Association; 2000.
15. Debruyne H, Portzky M, Peremans K, Audenaert K. Cotard's syndrome. *Mind Brain*. 2011;2:67-72.
16. Chiu HF. Cotard's syndrome in psychogeriatric patients in Hong Kong. *Gen Hosp Psychiatry*. 1995;17:54-5.
17. Ramirez-Bermudez J, Aguilar-Venegas LC, Crail-Melendez D, Espinola-Nadurille M, Nente F, Mendez MF. Cotard syndrome in neurological and psychiatric patients. *J Neuropsychiatry Clin Neurosci*. 2010;22:409-16.
18. Edelstyn NM, Oyeboode F. A review of the phenomenology and cognitive neuropsychological origins of the Capgras syndrome. *Int J Geriatr Psychiatry*. 1999;14:48-59.
19. Consoli A, Soultanian C, Tanguy M-L, Laurent C, Perisse D, Luque R, *et al*. Cotard's syndrome in adolescents and young adults is associated with an increased risk of bipolar disorder. *Bipolar Disord*. 2007;9:665-8.
20. Enoch D, Trethowan W. Cotard's syndrome. In: *Uncommon psychiatric syndromes*. 3rd ed. Oxford: Butterworth-Heinemann; 1991:162-83.
21. Pereira VB, Silva-Júnior EF. Etiology, drugs and incidence in Cotard syndrome. *J Chem Pharm Res*. 2016;8:579-85.

Das K, Liji P, Ryali VSSR. "Extant of the living dead": a case report on Cotard's syndrome and its treatment aspects from a tertiary care hospital in India. *Open J Psychiatry Allied Sci*. 2020 Feb 17. [Epub ahead of print]

Source of support: Nil. Declaration of interest: None.